

Early Detection and Treatment of Post-operative Perineal Hernia, Following APER, in a Community Setting

Maria Culleton, Community Stoma Care Nurse, Salts Healthcare

DEFINITION

A perineal hernia is a rare complication following major pelvic surgery. The hernia involves the perineum and occurs when the intra-abdominal viscera protrudes through a defect in the pelvic floor into the perineal region. It may contain fat, small bowel, colon, rectum and bladder.

Figs 1 and 2 show a normal perineal region following APER and one with a perineal hernia

CAUSES

Perineal hernias can occur spontaneously or following perineal surgery, such as APER, Panproctocolectomy, pelvic exenteration or sacrectomy.

It can also be caused by excessive straining, diarrhoea and constipation, prostate or urinary disease.

It occurs in only 0.34% to 7% of all APER's, and can be the result of inadequate reconstruction following surgery.

SYMPTOMS

The hernia can be asymptomatic or symptomatic, and presents with a swelling along the perineal scar.

This may cause pain, discomfort and a feeling of perineal fullness, or very little symptoms at all.

More worrying manifestations include urinary symptoms, breakdown of perineal skin and intestinal obstruction which may require emergency admission.

RISK FACTORS

- Perineal surgery
- Pre-operative radiotherapy
- Age
- Diabetes
- Obesity
- Cachexia
- Smoking
- Female gender

DIAGNOSIS

- Physical examination
- MRI scan
- CT scan

TREATMENT

Surgical repair can be either via an open transabdominal or transperineal approach, or a combination of both.

Methods include:

- Omentoplasty
- Synthetic mesh repair
- Musculocutaneous rotation flaps

Laparoscopic repair with the use of a prosthetic mesh is becoming increasingly popular. However there is a high level of recurrence due to poor anchoring of the mesh, infection, adhesions and formation of fistulae.

Patients with co-morbidities may be treated conservatively

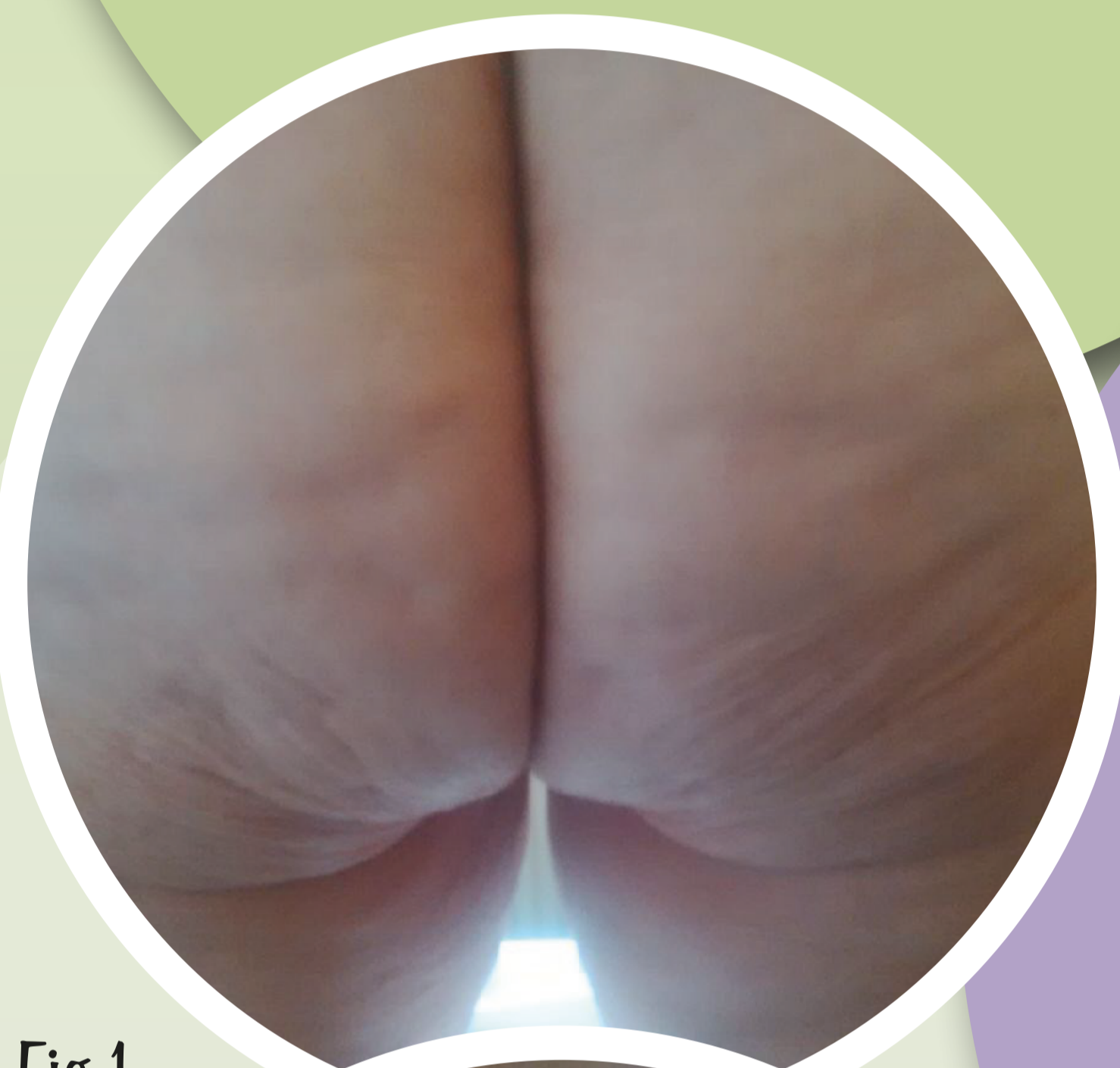


Fig 1

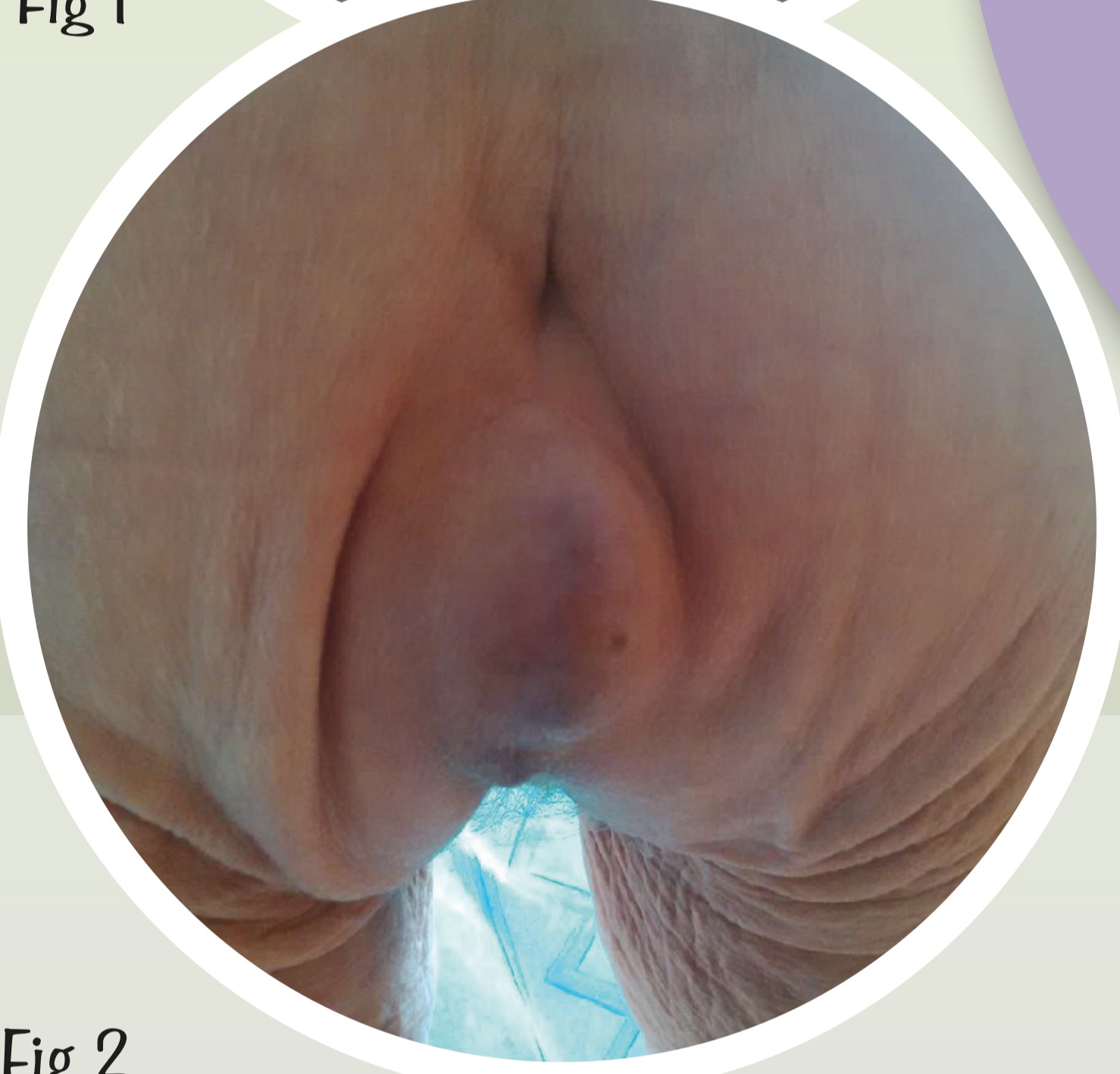

Fig 2

Check perineal scar at each visit when reviewing stoma

Scar intact no signs of redness, swelling or pain

Continue to monitor scar for at least a year postoperatively

Swelling and/or pain refer to either GP or Surgeon

Conservative management and use of support pants/boxer shorts
Watch and wait

Pain, no obvious swelling refer to GP or surgeon, possible recurrence

Repair of hernia and mesh insertion, Laparoscopic or abdominal surgery to correct fault

CT scan
MRI scan
Blood tests
surveillance

PATIENT A

Patient A is a 78yr old woman who presented with a small swelling along her perineal scar, almost a year post APER.

The patient had undergone both pre-operative chemotherapy and radiotherapy.

The hernia caused pain and discomfort and it was decided to repair it using a mesh laparoscopically.

The patient had successful surgery and her symptoms were relieved.

PATIENT B

Patient B is an 84yr old woman whose hernia was discovered at a routine postoperative visit by the stoma nurse, 3 months following APER having had pre-operative adjuvant therapy.

The patient was aware of mild discomfort and had been suffering from bouts of abdominal obstruction which had resolved spontaneously, but had required several short hospital admissions.

After seeing her surgeon it was decided to treat it conservatively.

REFERENCES

1. Journal of the Society of Laparoendoscopic Surgeons: Laparoscopic Repair of Perineal Hernia. Jessica MD Rayhanabad MD, Pejvak Sassani, Maher A Abbas MD
2. Laparoscopic Repair of Post-operative Perineal Hernia. Ali M Ghellaj, Saleem Islam, Mark E Stoker.
3. "Mesh Repair of a coccygeal hernia via an abdominal approach" Annals of the Royal College of Surgeons of England 82 (2): 113-5 Kumar A, Reynolds JR (2000)
4. E Aboian, D.C. Winter, D.R. Metcalf, and B.G. Wolff, "Perineal hernia after proctectomy: prevalence, risks, and management," Diseases of the Colon and Rectum, vol. 49, no. 10, pp. 1564-1568, 2006.
5. Laparoscopic Repair of Postoperative Perineal Hernia, Stephen Ryan, Dara O. Kavanagh, and Paul Neary. Case Reports in Medicine Volume 2010 (2010), Article ID 126483, 3 pages.